

## CASE REPORT

## A Case of Steven-Johnson Syndrome after Live Bee Acupuncture (Bong-Chim)

Yun-Jae Seol, Tae-Kyu Lee, Su-Jung Park, Sang-Uk Ko, Kyu-Hyung Kim, An-Soo Jang

Division of Allergy and Respiratory Medicine, Soonchunhyang University Bucheon Hospital, Bucheon, Korea

Bee stings can cause various skin reactions that usually resolve over several days; however, in some patients the venom acts as an allergen, causing a severe immunological response such as anaphylaxis. Bee stings can also induce chronic inflammation because the barbed stinging apparatus and venom sacs, along with the nerve plexus, can lodge in the skin. Chronic non-specific low back pain is the most common medical problem for which patients seek complementary and alternative medical treatment, including bee venom acupuncture. Bee venom acupuncture involves injecting diluted bee venom into acupoints and is used for arthritis, pain, and rheumatoid diseases. Here we report a 75-year-old man with acute urticaria and skin eruption with eosinophilia and interstitial pneumonia 6 weeks later after receiving 5 times bee venom acupuncture.

**Keywords:** Acupuncture; Bee venoms; Stevens-Johnson syndrome

## INTRODUCTION

The Hymenoptera order is divided into three families: Apids, Vespidae, and Formicidae. Apids include the honeybee, bumblebee, and sweat bee, which are all docile and tend to sting mostly on provocation [1]. The yellow jacket, yellow hornet, white (bald)-faced hornet, and paper wasp all belong to the Vespidae family. The Formicidae family includes the harvester ant and the fire ant.

When a 'bee' sting results in a large local reaction, defined as > 5 hours in and lasting > 24 hours, the likelihood of anaphylaxis from a future sting is about 5%. Reactions to Hymenoptera stings [1-5] are classified into normal local reactions, large local reactions, systemic anaphylactic reactions, systemic toxic reactions, and unusual reactions. The most frequent clinical patterns are large local and systemic anaphylactic reactions.

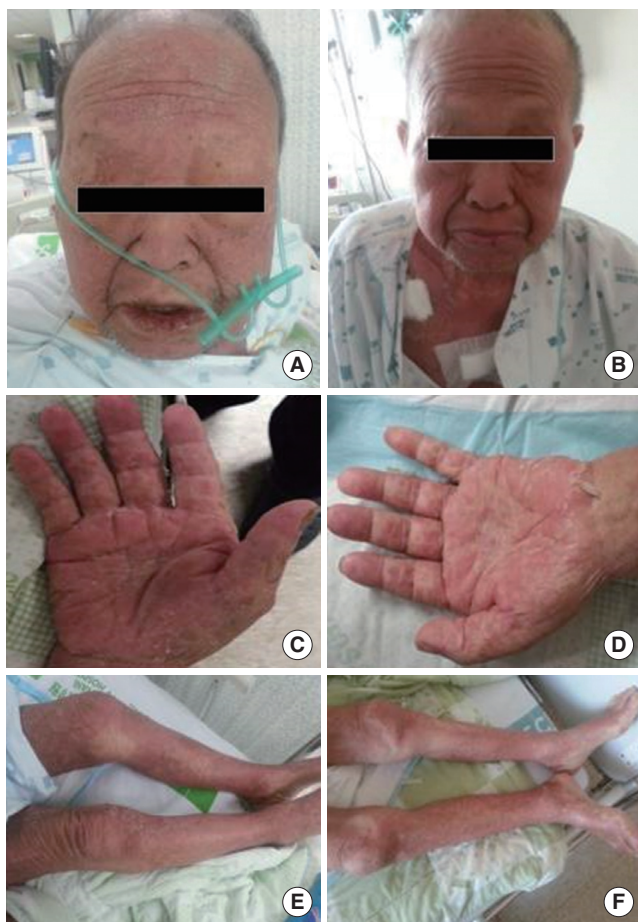Bee venom acupuncture (BVA) involves injecting purified and diluted bee venom into acupoints [6]. BVA exhibits several pharmacological actions, including analgesic, anti-inflammatory, anti-arthritis, and anti-cancer effects through multiple mechanisms, such as activation of the central inhibitory and excitatory systems and modulation of the immune system [7]. The analgesic effects of BVA have been reported in animal experiments [8] and in the clinic [9].

## CASE REPORT

A previously healthy 75-year-old man visited Soonchunhyang University Bucheon Hospital because of poor appetite due to oral ulcer. He had skin eruption, oral ulcer, urinary retention, and conjunctival itching. But he had no other remarkable medical history including allergy. On physical examination late inspiratory crackles in both lower lung fields auscultated. Generalized pruritic skin eruption showed in whole body. He had pruritic acute urticaria after acupuncture and then 2-6 weeks this skin lesion developed (Fig. 1A, C, E). The blood pressure was 125/75 mm Hg, the pulse 65 beats per minute, the oral temperature 36.5°C, the respiratory rate 18 breaths per minute, the oxygen saturation 95.7%, pH 7.447, PaO<sub>2</sub> 74.7 mm Hg, and PaCO<sub>2</sub> 28.1 mm Hg while the patient was breathing ambient air. An electrocardiogram revealed normal sinus rhythm. Pulmonary function test revealed forced expiratory volume in one second (FEV<sub>1</sub>)/forced vital capacity (FVC) 97%, FVC 1.28 L (41%), FEV<sub>1</sub> 1.32 L (60%), and diffusing capacity for carbon monoxide 15.1 mL/mm Hg (71%) indicating restrictive pattern. Chest radiographs revealed bilateral patchy opacities, more in the right lung than in the left lung. Computed tomography of the chest revealed multifocal consolidation and ground-

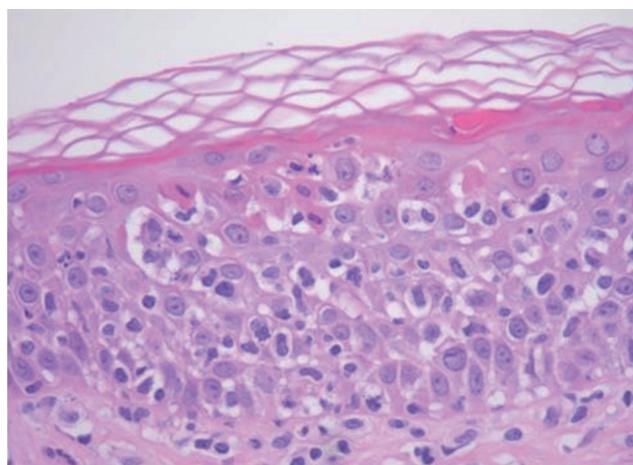
Correspondence to: An Soo Jang  
Division of Allergy and Respiratory Medicine, Soonchunhyang University Bucheon Hospital, Soonchunhyang University College of Medicine,  
170 Jomaru-ro, Wonmi-gu, Bucheon 14584, Korea  
Tel: +82-32-621-5114, Fax: +82-32-621-5018, E-mail: jas877@schmc.ac.kr  
Received: Oct. 29, 2015 / Accepted after revision: Nov. 25, 2015

© 2015 Soonchunhyang Medical Research Institute  
This is an Open Access article distributed under the terms of the  
Creative Commons Attribution Non-Commercial License  
(<http://creativecommons.org/licenses/by-nc/3.0/>).

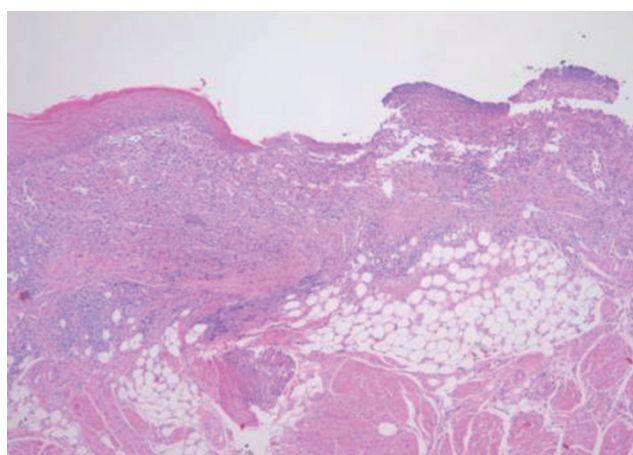


**Fig. 1.** Before and post-treatment. (A, C, and E) Lesions on face and extremity were angioedema and skin eruption and exfoliation before treatment and (B, D, and F) skin lesions were subsided and desquamation sustained for 2 weeks after treatment. Skin detachment was < 10 percent of the body surface.

glass opacities in all lobes of both lungs. Computed tomography of the abdomen revealed small and large bowel was dilated including air and lots of fluid, likely infectious enterocolitis. Total immunoglobulin E (IgE) was 623 kU/L. The patient underwent skin-prick testing 14 days after the event. Specific IgE for *Dermatophagoides farinae*, *Dermatophagoides pteronyssinus*, cat fur, dog fur, mugwort, and ragweed were negative. We carried out bronchoscopy and the result was no endobronchial lesion. Bronchoalveolar lavage revealed macrophage 17.20%, neutrophil 71.60%, and eosinophil 11.20%. We have considered the possibility of Stevens-Johnson syndrome following 5 times BVA history and he had whole body skin eruption, oral ulcer, and interstitial pneumonia. Punch biopsies were taken from the skin lesion on chest and tongue. Microscopically, the skin biopsy specimen showed orthokeratotic hyperkeratosis, superficial dermal lymphocytic infiltration with lym-



**Fig. 2.** Scattered necrotic keratinocytes on skin biopsy (H&E, × 400).



**Fig. 3.** The surface epithelium of the tongue is ulcerated (H&E, × 40).

phocytic exocytosis, and scattered necrotic keratinocytes (Fig. 2). Biopsy of the tongue lesion showed severe ulceration of surface epithelium with inflamed granulation tissue (Fig. 3).

The patients were diagnosed as Stevens-Johnson syndrome and treated with systemic steroid and anti-histamine. Lots of skin lesions were subsided and angioedema was disappeared (Fig. 1B, D, F). Redness was subsided and desquamation was sustained for 2 weeks. He was informed of the results and of the risk for bee venom in the future.

## DISCUSSION

Venom hypersensitivity [1-5], as defined in the recently revised nomenclature for allergy, may be mediated by immunologic mechanisms (IgE-mediated or non-IgE-mediated venom allergy) but

also by nonimmunologic mechanisms.

Venom hypersensitivity diagnosis [5] should be collected on: number and date of sting reactions, sort and severity of symptoms, interval between sting and the onset of symptoms, emergency treatment, sting site, retained or removed stinger, environment and activities before sting, risk factors of a particular severe reaction, risk factors for repeated re-stings, tolerated stings after the first systemic reactions, and other allergies.

The skin, the gastrointestinal, respiratory, and cardiovascular systems can be involved. Severe reactions or a status after resuscitation may leave patients with a permanent disorder: hypoxic brain damage with permanent neurologic deficits, and myocardial infarction [5]. For comparison, when there is a history of anaphylaxis from a previous Hymenoptera sting and the patient has positive skin tests to venom, at least 60% of adults and 20% to 32% of children will develop anaphylaxis with a future sting [1-4]. Both patient groups should be instructed about avoidance measures and carrying and knowing when to self-inject epinephrine, but immunotherapy with Hymenoptera venom is indicated for those patients with a history of anaphylaxis from the index sting and not for patients who have experienced a large local reaction [1].

Bee venom acupuncture has been used in Korea to relieve various pain symptoms. Bong-Chim therapy [10] can be used for various diseases. Bong and Chim are Sino-Korean words meaning bee and stinger or acupuncture. There are two modalities in Bong-Chim therapy. One is live bee acupuncture, which applies honeybee (*Apis cerana*) stingers directly into the lesion, and the other is injection of extracted bee venom into the lesion with a syringe. The former is a traditional and popular modality, whereas the latter has only recently been attempted. Many people who have received live bee acupuncture therapy have reported skin symptoms, which are called Bong-Chim dermatitis, and more precisely defined as live

bee acupuncture dermatitis. The acute stage is an inflammatory reaction, such as anaphylaxis or urticaria. In the chronic stage, a foreign body granuloma may develop from the remaining stingers, similar to that of a bee sting reaction. The subacute phase, the characteristic histological flame figures as a characteristic feature of live bee acupuncture dermatitis that is different from the adverse skin reaction of accidental bee sting [10]. In this case acute and subacute stage, the characteristic urticaria, angioedema and Steven Johnson syndrome show as a characteristic feature of live bee acupuncture dermatitis that is different from previous report [7].

## REFERENCES

1. Koterba AP, Greenberger PA. Chapter 4: stinging insect allergy and venom immunotherapy. *Allergy Asthma Proc* 2012;33 Suppl 1:S12-4.
2. Hamilton RG. Diagnosis and treatment of allergy to hymenoptera venoms. *Curr Opin Allergy Clin Immunol* 2010;10:323-9.
3. Muller UR. Insect venoms. *Chem Immunol Allergy* 2010;95:141-56.
4. Biló MB. Anaphylaxis caused by Hymenoptera stings: from epidemiology to treatment. *Allergy* 2011;66 Suppl 95:35-7.
5. Biló BM, Rueff F, Mosbech H, Bonifazi F, Oude-Elberink JN; EAACI Interest Group on Insect Venom Hypersensitivity. Diagnosis of Hymenoptera venom allergy. *Allergy* 2005;60:1339-49.
6. Son DJ, Lee JW, Lee YH, Song HS, Lee CK, Hong JT. Therapeutic application of anti-arthritis, pain-releasing, and anti-cancer effects of bee venom and its constituent compounds. *Pharmacol Ther* 2007;115:246-70.
7. Baek YH, Huh JE, Lee JD, Choi do Y, Park DS. Antinociceptive effect and the mechanism of bee venom acupuncture (Apipuncture) on inflammatory pain in the rat model of collagen-induced arthritis: mediation by alpha2-adrenoceptors. *Brain Res* 2006;1073-1074:305-10.
8. Chen HS, Qu F, He X, Liao D, Kang SM, Lu SJ. The anti-nociceptive effect and the possible mechanism of acupoint stimulation caused by chemical irritants in the bee venom pain model. *Brain Res* 2010;1355:61-9.
9. Lee JD, Park HJ, Chae Y, Lim S. An overview of bee venom acupuncture in the treatment of arthritis. *Evid Based Complement Alternat Med* 2005; 2:79-84.
10. Park JS, Lee MJ, Chung KH, Ko DK, Chung H. Live bee acupuncture (Bong-Chim) dermatitis: dermatitis due to live bee acupuncture therapy in Korea. *Int J Dermatol* 2013;52:1519-24.