

**COMPARATIVE STUDIES
ON THE ANTIMICROBIAL ACTIVITY OF PROPOLIS BALM
AND SILVER SULPHADIAZINE
APPLIED TO BURN WOUNDS IN PIGS**

AGATA KABAŁA – DZIK¹, EWA SZAFLARSKA – STOJKO¹,
ROBERT D. WOJTYCZKA³, ARTUR STOJKO²,
RAFAŁ STOJKO¹ AND JERZY PACHA³

¹Department of Pathology,

²Department of Bioanalysis and Environmental Research,

³Department of Microbiology,

Faculty of Pharmacy, Medical University of Silesia,

41 - 200 Sosnowiec, Poland

e- mail: ¹adzik@slam.katowice.pl, ³mikrob@infomed.slam.katowice.pl

Received for publication May 26, 2003.

Antibacterial activity of propolis balm and silver sulphadiazine applied onto burn wounds in 2 pigs of *biała zwiśloucha* breed was compared. The efficiency assessment was based on the clinical and microbiological examination.

Key words: swine, burn wounds, propolis, antimicrobial activity.

The apitherapeutics are products obtained from bees. Many clinical observations and experiments proved their biotic influence on the human organism. They have immunomodulating, cell stimulating, regenerative, detoxifying, and antibacterial properties (5).

Propolis is a resinous hive product collected by honeybees from various plant sources. It is popular in folk medicine due to its broad spectrum of biological activities. Many scientific articles related to the pharmacological properties of propolis mention its antihepatotoxic, antitumour, antioxidative, antimicrobial, and anti-inflammatory properties (1, 4). Propolis showed good antimicrobial activity against many bacteria, particularly *Streptococcus pneumoniae*, *Haemophilus influenzae* and *Moraxella catarrhalis*, but not against *Enterobacteriaceae* (2).

The infection of burn wounds with multiple organisms, with superadded problem of drug resistance, indicates the institution of a drug policy by the hospitals for burned patients (8). Gram-positive

bacteria are predominant in colonization of the burn wounds. In the patients with more than 40% of total body surface burned, *Staphylococcus aureus* was the most frequently isolated organism (10). The significant role of *Candida albicans* in the infection of burn wounds was underlined (6). In those wounds the most commonly isolated organisms were *Staphylococcus aureus* and *Pseudomonas* (3).

Skin burn wounds appear to be the perfect model for the clinical examination and laboratory testing of healing and antimicrobial properties of drugs. Therefore, antimicrobial activity of propolis balm applied onto burn wounds in pigs was evaluated on the basis of clinical and microbiological examinations.

Material and Methods

Two pigs of *biała zwiśloucha* breed, 30-40 kg of body weight and 15-16 weeks old, were used in the experiment.

The model of the burn wound was prepared according to Hoekstra standard. Each pig was burned superficially for 10 s in the symmetrical distance with hot (170° C) brass brick (450 g) at 9 places on each side. Every burn wound was 1.5x3 cm of size and the total burned surface did not exceed 10% of the body surface. Before burning, the pigs were put to general anesthesia with 1 mg/20 kg b.w. of atropine sulphate, 0.1 ml/kg b.w. of 2% Sedazin (Xylazinum) and 10 mg/kg b.w. of Bioketan (ketamine hydrochloride).

The burn wounds regarded as experimental ones were treated once a day with 1% propolis balm, prepared on standard medium. The control burn wounds were treated with 1% silver sulphadiazine (SSD), applied also once a day.

For microbiology examination the swabs were taken from the burn wounds on 1, 3, 5, 10 and 15 d of the experiment using transport media for aerobic and anaerobic bacteria. The samples were analyzed by culture, microscopic examination and biochemical tests (API-bioMérieux), according to NCLS standards. Quantitative and qualitative analyses were performed. At the same time microbiological control of skin and propolis balm was performed.

In the clinical assessment of the healing process of after-burn wounds, observations concerned the appearance, size of wound area, and skin in their neighbourhood, and furthermore, the process of granulation and formation of the crust occurring on the surface of wounds.

The experiment was performed according to the rules of Good Laboratory Practice and was accepted by the Regional Ethical Board for Experiments on Animals.

Results

Results of clinical examinations. Observations and examination concerning general condition of animals and wound healing process are presented in Table 1.

For the first twenty-four hours the analgesic medications were administered to eliminate an eventual pain feeling in animals. In the next days of the experiment, the animals showed a normal reaction to the environment and revealed no symptoms of suffering from the after-burn wounds.

Table 1
Comparison of healing process in pigs

Day	1% propolis balm	1% silver sulphadiazine (SSD)
1, 3, 5	Clinical image was similar. Inflammation with large quantity of exudation and swelling of skin surrounding the place of scald was accompanied by necrotic changes..	
15	Areas of wounds markedly diminished to 1.0 x 2.5 cm and were coated with a delicate epidermis with light pink colour.	Crusts were still adhered to the surface of wounds. On edges they came from wound surface. In these places an epidermis appeared with a red tint what could indicate the scar. The area of wounds did not diminish.
20	Wounds were healed.	Crusts came off the surface of wounds. Under the crusts there were reddened scars. Size of the wounds did not change.

Results of bacteriological examinations. The following microorganisms were isolated during the first 24 h from wounds treated with propolis balm: *Staphylococcus aureus*, *Staphylococcus epidermidis*, *Enterococcus faecalis*, *Bacillus* spp., and *Candida albicans*. Their growth was observed for the next days of the experiment until day 10. On day 15 only the growth of *Staphylococcus aureus* and *Candida albican* was continued.

In the wounds treated with SSD, in the first twenty-four hours of the experiment, the growth of *Staphylococcus aureus* and *Enterococcus faecalis* was observed. Presence of these species was demonstrated also on the 3rd, 5th and 10th d of the experiment. However, on day15 only *Staphylococcus aureus* was isolated.

Simultaneously, the quantitative examinations of bacterial flora in the after-burn wounds were conducted. In wounds treated with propolis balm the number of microbes existing on 1 cm² of the wound in the first

24 h was 1×10^5 and increased up to 1×10^6 on the 3rd d. This number was stable till the 5th d of the experiment. However, on the 10th d it decreased considerably to 6×10^5 and on day 15 dropped to 2×10^4 . This value was smaller than the initial one, what showed that the use of propolis balm decreased the number of microbes existing in the first 24 h of the experiment.

In the wounds treated with SSD – in the first 24 h the number of microbes was 2×10^4 and gradually increased during the following days of examination to reach 6×10^5 on day 5. On the 10th d the number of microbes began to decrease imperceptibly and on day 15 its value was 2×10^5 . The results of microbiological examinations are showed in Fig. 1.

Microbiological examinations of the skin performed before the use of the preparations revealed the presence of *Staphylococcus aureus* and *Candida albicans* organisms. Their number ranged from $2 \times 10^4 / \text{cm}^2$ to $9 \times 10^4 / \text{cm}^2$.

Quantitative examinations of microbiological sterility of preparations showed no presence of any pathogenic microbes.

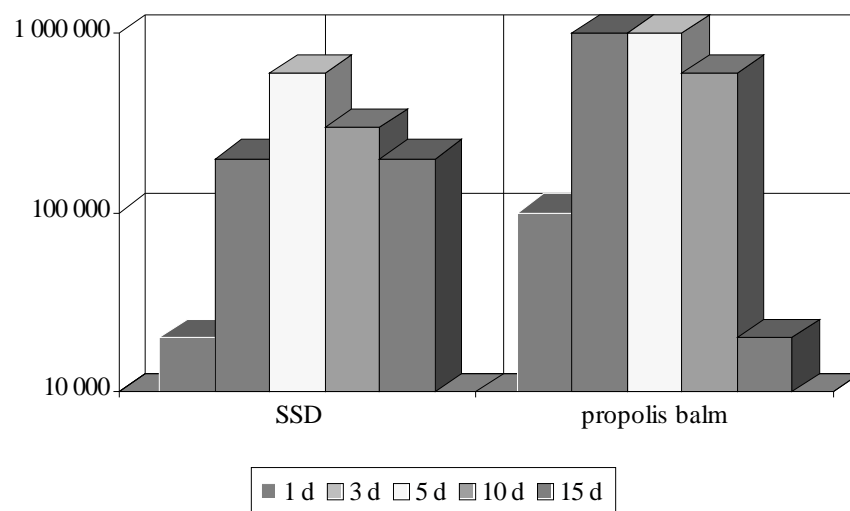


Fig. 1. Total number of all isolated bacteria from burn wounds.

Discussion

Our clinical observation and bacteriological examinations demonstrated that propolis balm was more effective than SSD. Propolis samples from different geographic areas were investigated for their antibacterial, antifungal and antiviral activities (5).

These results could explain the observed therapeutic properties of propolis in the promoting of the wound healing. We observed in our clinical examinations that the wounds treated with propolis balm, were healed after 20 days. At the same time in wounds treated with SSD the crusts came off the surface of wounds and under the crusts there were reddened scars. Size of the wounds did not change.

Tsarev *et al.* (9) reported that the propolis used in the routine treatment of infected wounds displayed a stimulating, anti-inflammatory, and antimicrobial activity. Scheller *et al.* (7) demonstrated a synergistic effect of propolis on the growth of *Staphylococcus aureus* and synergism and correlation between ethanolic extract of propolis and some antituberculosis drugs.

Our obtained till now results demonstrated the bacteriostatic activity of the examined apitherapeutic drug in relation to *Staphylococcus aureus* and the germicidal activity in relation to: *Bacillus spp.*, *Ent. faecalis*, and *Candida albicans*.

On the basis of our clinical experiments and bacteriological analysis it should be supposed that propolis balm has an unquestionable influence on the healing process of after-burn wounds, accelerating recovery processes. The tests let us to make an initial comparative assessment of the preparations used. Our examinations clearly showed that propolis balm profitably influences the healing process of after-burn wounds in comparison with the universally used SSD.

References

1. Banskota A.H., Tezuka Y., Kadota S.: Recent progress in pharmacological research of propolis. *Phytother. Res.*, 2001, **15**, 561–571.
2. Drago L., Mombelli B., De Vecchi E., Fassina M.C., Tocalli L., Gismondo, M.R.: *In vitro* antimicrobial activity of propolis dry extract. *J. Chemother.*, 2000, **12**, 390–395.
3. Kaushik R., Kumar S., Sharma R., Lau P.: Bacteriology of burn wounds – the first three years in a new burn unit at the Medical College Chandigarh. *Burns*, 2001, **27**, 595–597.
4. Król W., Czuba Z., Scheller S., Gabryś J., Grabiec S.: Antioxidant property of ethanolic extract of propolis (EEP) as evaluated by inhibiting the chemiluminescence oxidation of luminol. *Biochem. Int.*, 1990, **21**, 593–597.
5. Kujumgiev A., Tsvetkova I., Serkedjieva Y., Bankova V., Christov R., Popov S.: Antibacterial, antifungal and antiviral activity of propolis of different geographic origin. *J. Ethnopharmacol.*, 1999, **64**, 235–240.
6. Mousa H.A., al-Bader S.M.: Yeast infection of burns. *Mycoses*, 1999, **44**, 147– 49.

7. Scheller S., Dworniczak Sz., Klimek W., Rajca M., Tomczyk A., Shani J.: Synergism between ethanolic extract of propolis (EEP) and antituberculosis drugs on growth of mycobacteria. *Z. Naturforsch.*, 2001, **54**, 549–553.
8. Sharma S., Hans C.: Bacterial infections in burns patients: a three years study at RML Hospital, Dehli. *J. Commun. Dis.*, 1996, **28**, 101-106.
9. Tsarev N.I., Petrik E.V., Aleksandrova V.I.: Use of propolis in the treatment of local suppurative infection. *Vest. Khir. I I Grek*, 1985, **134**, 119–122.
10. Winkler M., Erbs G., Muller F.E., Konig W.: Epidemiologic studies of the microbial colonization of severely burned patients. *Zentralbl. Bakteriol. Mikrobiol. Hyg.*, 1987, **184**, 304–320.